

2. Garcia-Zuazaga J. Pseudofolliculitis barbae: Review and update on new treatment modalities. *Mil Med.* 2003;168:561–564.
3. Lumley C. Intraoral hair removal on skin graft using Nd:YAG laser. *Br Dent J.* 2007;203:141–142.
4. Fairclough JA, Johnson D, Machie I. The prevention of wound contamination by skin organisms by the pre-operative application of an iodophor impregnated plastic adhesive drape. *J Int Med Res.* 1986; 14:105–109.

Surgical Correction of a Mild Helical Rim Deformity

Sir:

Only a few articles are available in the English literature dealing with the treatment of minor surgical ear deformities. Congenital auricular anomalies can be categorized as either malformational or deformational. Deformational auricular anomalies often result from abnormal in utero or ex utero forces acting on the newly formed auricular cartilage framework. In this form of auricular anomalies, all ear components are present and the deformed auricular shape can be restored to normal or near normal by digital manipulation in newborns, when the auricular cartilage is still malleable.¹ These auricular deformities, when stabilized in the adult, need surgical correction.

We have previously classified deformational auricular anomalies as vertically, horizontally, or focally deformed (types 1, 2, and 3a and 3b). In that scheme, the term “deformed” was intended as “limitation” to the external ear shape development.²

A 25-year-old patient presented to our clinic with a left unilateral ear deformity affecting mainly the upper pole. The upper third of the helical rim was flattened and was concave instead of convex for an extension of 3.5 cm. The ear was normal in dimen-

sions and size and was not protruding. All of the other auricular structures were normal. The patient had not had any surgery before. We classified this auricular anomaly as type 3a according to our previously described classification: it appeared that a single imprint had caused the inversely folded helical deformity (Fig. 1, *left*).

Surgical correction was performed under local anesthesia. A posterior incision was used to expose the cartilage deformity. Subcutaneous undermining was extended beyond the boundaries of the deformed cartilage segment. The helical rim was isolated and detached from the rest of the auricle (Fig. 2, *left*); this segment was reshaped by scoring, then turned upside down and rotated 180 degrees on itself. The helical rim segment was resutured in place as a cartilage graft with 6-0 Monocryl (Ethicon, Inc., Somerville, N.J.) separated stitches (Fig. 2, *right*). Skin was re-draped on the new helical rim cartilage graft. Bolster sutures were used to hold the skin onto the repositioned helical rim. A head bandage completed the procedure. Satisfactory correction was stable at 18-month follow-up (Fig. 1, *right*). In Saad's book, different options for helical rim reconstruction with either cartilage flap or cartilage graft in burned ears are well described.³

Nagata described a case of a minor-degree constricted ear similar to ours, treated with expansion of the helical circumference by multiple incisions completed with helical rim graft remodeling.⁴ Sugino et al. presented correction of a different type of ear deformity, Stahl's ear, using the cartilage turnover and rotation method.⁵ The principle of using pathologic tissue as a source for cartilage graft is not new. Plastic surgeons are familiar with septal cartilage remodeling by means of complete removal of deviated

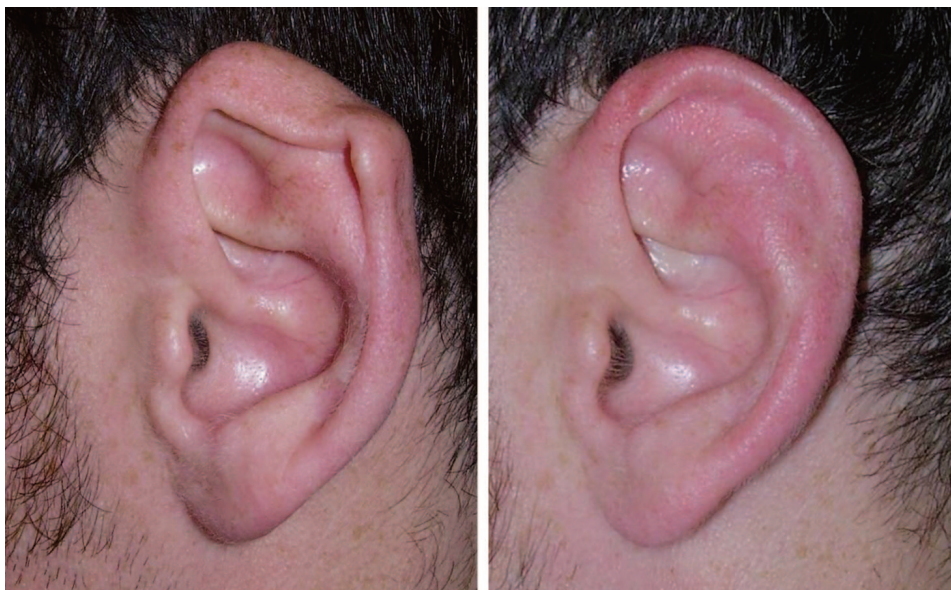

Fig. 1. (*Left*) Left unilateral deformational auricular anomaly. (*Right*) Follow-up at 18 months.

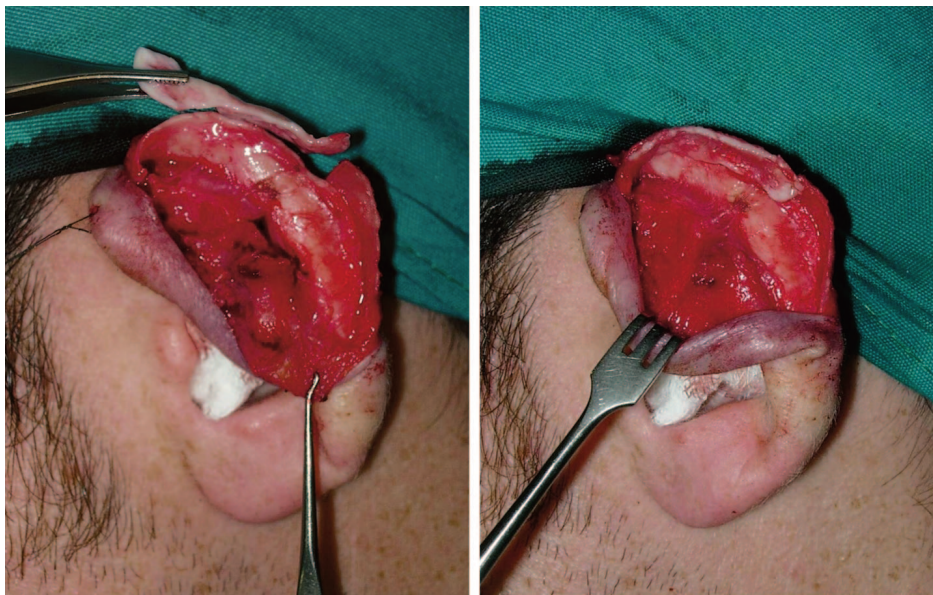


Fig. 2. Intraoperative views of the exposed auricular cartilage and its replacement by a helical rim cartilage graft.

septum and repositioning after correction in septorhinoplasty operations.

Our surgical method has put together different ideas—but at the same time, it is simple and effective, going directly to the anatomical correction of the deformity.

DOI: 10.1097/PRS.0b013e3181d45d42

Fabrizio Schonauer, M.D., Ph.D.

Adriano Santorelli, M.D.

Sergio Marlino, M.D.

Luigi Canta, M.D.

Guido Molea, M.D., Ph.D.

Department of Plastic Surgery
University Federico II
Naples, Italy

Correspondence to Dr. Schonauer
Via Andrea d'Isernia N°4
80122 Naples, Italy
fschona@libero.it

REFERENCES

1. Lindford AJ, Hettiaratchy S, Schonauer F. Postpartum splinting of ear deformities. *BMJ*. 2007;334:366–368.
2. Schonauer F, La Rusca I, Molea G. Non-surgical correction of deformational auricular anomalies. *J Plast Reconstr Aesthet Surg*. 2008;62:876–883.
3. Saad MN. *Operative Plastic and Reconstructive Surgery*. New York: Churchill Livingstone; 1980:315–316.
4. Nagata S. Alternative surgical methods of treatment for the constricted ear. *Clin Plast Surg*. 2002;29:301–315.
5. Sugino H, Tsuzuki K, Bandoh Y, Tange I. Surgical correction of Stahl's ear using the cartilage turnover and rotation method. *Plast Reconstr Surg*. 1989;83:160–164.

It Is Time to Reconstruct Human Auricle More Precisely and Microinvasively

Sir:

Total external ear reconstruction using autologous costal cartilage placed in a subcutaneous pocket was first described by Gillies and refined by Tanzer, Brent, and others. The technique remains the most definitive standard for total external ear reconstruction at present; however, it has obvious limitations, including a long learning curve, an often lengthy operation, a construct that is often asymmetrical to the healthy side, and donor-site morbidity. The use of an alloplastic material (Medpor; Porex Surgical, Inc., Newnan, Ga.) framework brings the obvious advantages of predictability in construct size and shape, avoidance of donor-site morbidity, and thus decreased operative time; however, alloplastic materials are predisposed to extrusion and infection because of poor biological integration.

Tissue engineering technology provides the possibility of creating an auricular framework that is more precise and microinvasive for auricular reconstruction. Practically, many experimental studies have shown the prospect of this technique. Cao et al. reported the generation of cartilage in the shape of a human ear 12 weeks after subcutaneous delivery of bovine chondrocytes in polyglycolic acid polymers into nude mice¹; Kamil et al. then constructed ear-shaped cartilage with gold molds in a bovine model that is immunocompetent.² Neumeister et al. successfully generated vascularized ears,³ although they lacked the exact shape and size for clinical use. Morphologically, advances in computer and imaging techniques have led to computer-aided design and manufacturing to be an established method. This technology can be introduced into typical one-side mi-